

# BRONCHOGENIC CYST: MIMICKING PLEURAL EFFUSION

Kausar Rehana\*, Amarah Pervaiz\*, Muhammad Mudassir Shafiq\*

\* Department of Pulmonology, Pakistan Institute of Medical Sciences, Islamabad - Pakistan

Address for correspondence:

**Kausar Rehana**

Department of Pulmonology, Pakistan Institute of Medical Sciences, Islamabad - Pakistan

E mail: drkr701@yahoo.com

## ABSTRACT

**Introduction:** Bronchogenic cyst is a rare clinical entity that occurs due to abnormal development of the foregut; the majority of bronchogenic cysts have been described in the mediastinum and they are rarely found in an extrathoracic location.

**Case presentation:** We describe the case of an intra-pleural bronchogenic cyst, incidentally discovered during elective thoracic surgery for pleurectomy to remove the cause of recurrent pleural effusion in a 33-year-old lady.

**Conclusions:** The parietal and visceral pleural bronchogenic cysts are very uncommon but should be considered as a differential diagnosis of lesions originated from pleural cavity.

**Key words:** Bronchogenic cyst; Pleural effusion.

This case report may be cited as: Rehana K, Pervaiz A, Shafiq MM. Bronchogenic CYST: Mimicking pleural effusion. Pak J Chest Med 2016; 22 (3): 117-20.

## INTRODUCTION

The laryngotracheal groove shows up toward the end of the third week of growth in the embryonic foregut; the dorsal bud of the foregut stretches to form the esophagus, and the ventral divide eventually separates into the respiratory tract, with ciliated epithelium lining both the fetal esophagus and trachea.<sup>1-3</sup> Bronchogenic cyst and esophageal duplications are clinical distortions because of abnormal development of the foregut.

Bronchogenic cyst structure from adornment ventral buds emerging from the foregut distal to the future lung at about the fifth week of intra-uterine life; the lion's share of bronchogenic cysts have been portrayed in the mediastinum (90%, most normally in the back part of the prevalent mediastinum)<sup>4-8</sup> and they are once in a while found in an extrathoracic area.

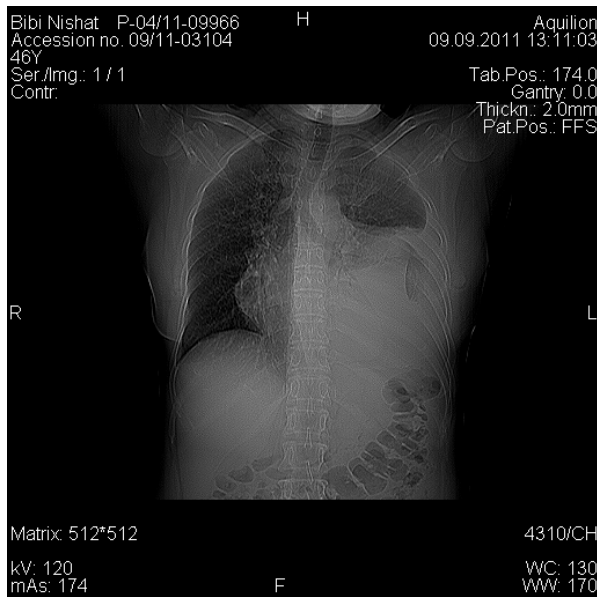
We report a bronchogenic cyst incidentally discovered during thoracic surgery for pleurectomy in our patient, who was admitted to our pulmonary unit for recurrent pleural effusion

## CASE REPORT

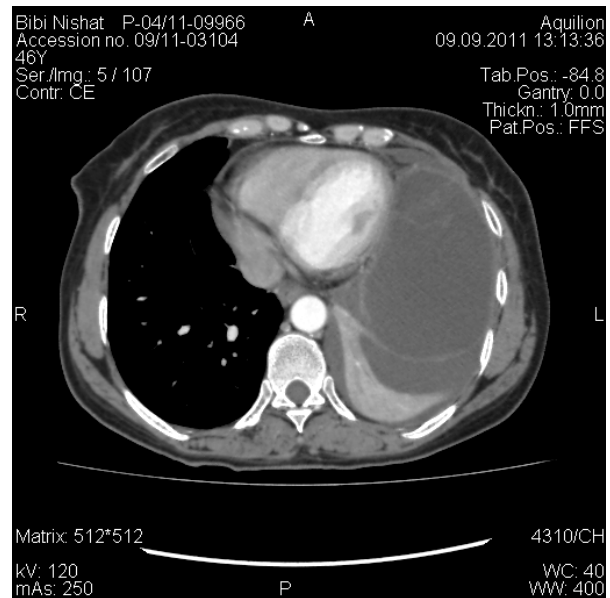
A 46 year old lady presented to pulmonology OPD PIMS through referral. History dates back some 2 years back when she was diagnosed as a case of tuberculous pleural effusion on the basis of chest x-ray that showed large effusion on left side. She took ATT for 9 months but no clinical or radiological improvement documented. Then chest USG was done that showed large pleural effusion and moderate

pericardial effusion. At this time she was put on ATT with steroids. She took for 6 months but no improvement, so she was referred to us. She was admitted with large left pleural effusion, etiology unknown. Diagnostic pleural tap came to be transudative lymphocytic. Pleural biopsy was done that reported as and therapeutic tap was done. CT Scan chest reported as loculated empyema. She was discharged on antibiotics. But after 1 week she again presented with SOB. This time her CXR was same as at time of previous admission. diagnostic tap this time was exudative, pleural biopsy showed and fluid was drained with chest intubation. Again she was discharged with antibiotics. She again admitted after 10 days with same complains. CXR was again same as previously. Fluid was exudative, biopsy showed congestion and fibrosis and 2300ml fluid drained through chest tube. Bronchoscopy was done that showed hyperemic Rt.main bronchus. Biopsy showed congestion. Surprisingly she remained afebrile, maintained her weight throughout this long period. Hydatid serology, autoimmune profile, ESR/CRP, TB workup, fluid triglyceride and eosinophil count, all were normal. She refused to VATS due to financial constrains. Then she was referred to thoracic surgeon for pleurectomy. On surgery table, a large cyst was found in left hemithorax (fig.2). Dissected and histopathology reported as "Bronchogenic cyst". CT Scan chest reformatting showed pedicle with large cyst (fig.1). Post operatively, she remained stable and discharged. Follow up CXR, condition was alright and she had no more symptoms.

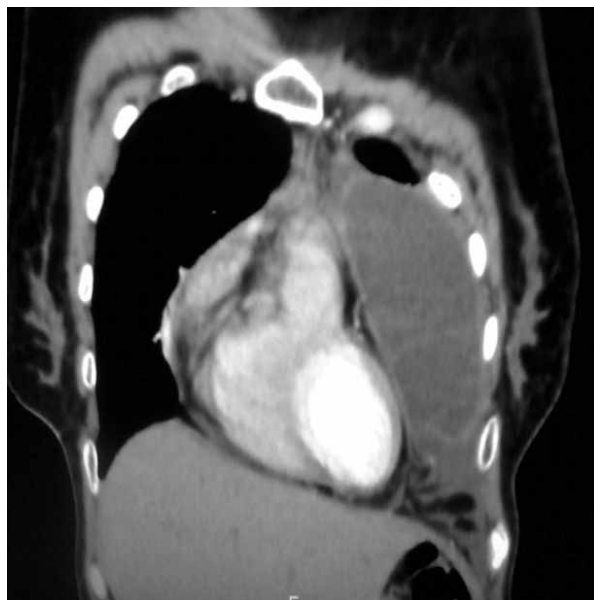Figure 1: Chest radiology (A) showing homogenous opacity filling 2/3 of left hemithorax. CT Chest with contrast (B) axial view showing fluid in the cysts having an average CT density of 0 Hounsfield units, with internal septations (C) coronal view showing rounded well circumscribed cyst compressing adjacent lung parenchyma and reactive pleura effusion (D) saggital section showing pedicle high up in the mediastinum.



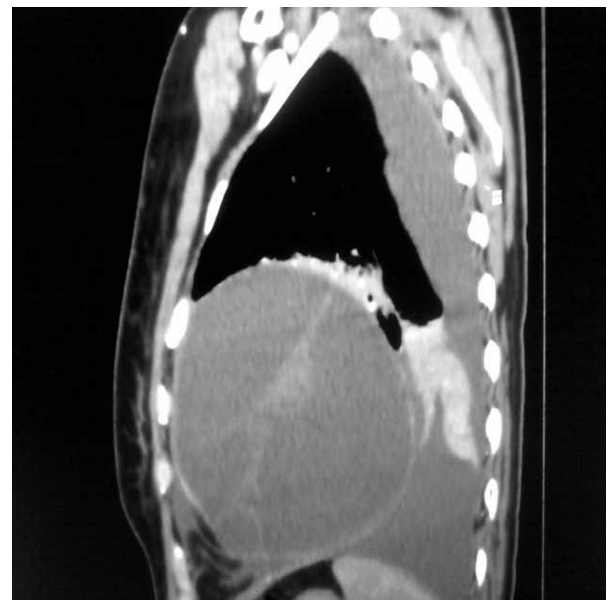
(a)



(b)



(c)



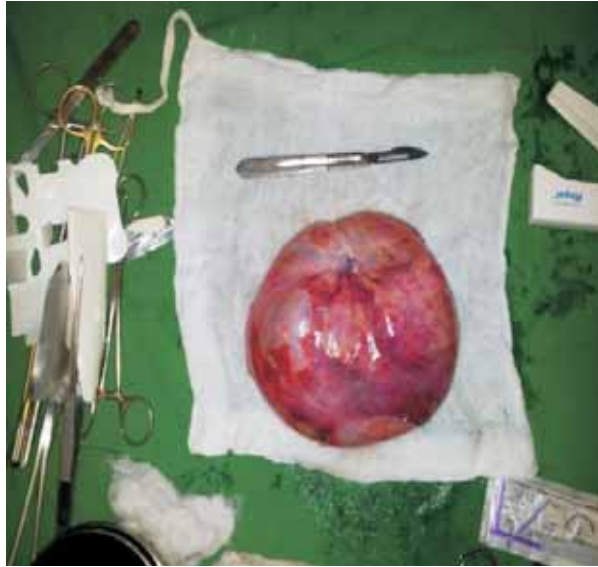(d)

## DISCUSSION

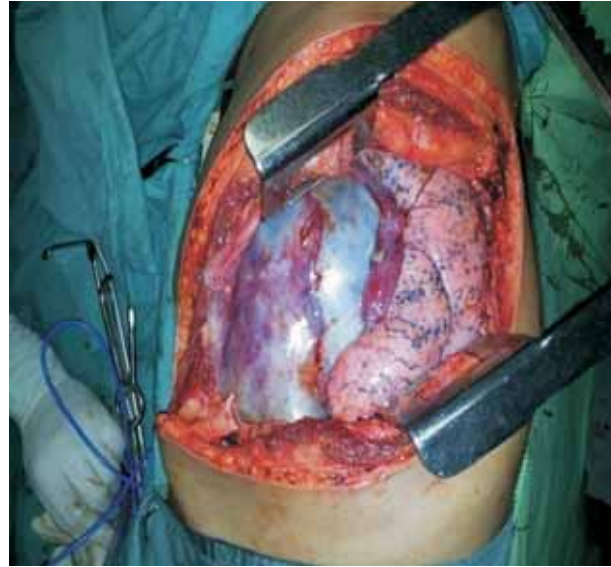Bronchogenic cyst begin from an adornment lung bud of the primitive foregut after the third week of embryonic life. Most regularly they relocate caudally with the esophagus and are in the end found in the posterior mediastinum close to the carina, connected to the tracheobronchial tree or to the esophagus.

Infrequently the growth may isolate totally from its starting point and might be found in strange locales, for example, pericardium, skin.<sup>9,10</sup> There have been just a couple reports of bronchogenic cysts that emerged from the pleura. McAdams et al<sup>11</sup> reported 68 instances of bronchogenic cysts and just 1 cyst (1.5%) was found neighboring the pleura and this element has not been talked sufficiently about picture discov-

Figure 2: (A) Open thoracotomy, a large bronchogenic cyst in left hemithorax with peduncle attached in mediastinum. (B) Bronchogenic cyst after excision with intact capsule, filled with fluid.



(a)



(b)

eries and histologic elements. On CT, bronchogenic cysts have been accounted for to show unenhanced cyst at or close water (0 to 20 HU) to high (containing concentrated mucous or discharge) thickness and smooth wall.<sup>12,13</sup> Nakagawa et al reported two cases of bronchogenic cyst with similar peduncle/stalk attached to parietal pleura.<sup>14</sup> We emphasize that the visceral and parietal pleural bronchogenic cysts might occur and show similar radiologic features to those of pleural origin coelomic cysts or may mimic pleural effusion.

## CONCLUSION

The parietal and visceral pleural bronchogenic cysts are very uncommon but should be considered as a differential diagnosis of lesions originated from pleural cavity

## REFERENCES

1. Skandalakis JE, Gray SW, Ricketts R: The esophagus. In *Embryology for Surgeons*. Edited by: Skandalakis JE, Gray SW. Baltimore, MD: Williams and Wilkins 1994; 65-112.
2. Moore TE, Parson. *The developing human. Clinically Oriented Embryology* Philadelphia, PA: WB Saunders 1993; 628-644.
3. DeLorimier AA: Congenital malformations and neonatal problems of the respiratory tract. In *Pediatric Surgery*. Edited by: Welch KJ, Randolph JG, Ravitch MM, et al. Chicago, IL: Yearbook Medical Publishers 1986; 631-648.
4. Laberge JM, Puligandla P, Flageole H: Asymptomatic congenital lung malformations. *Semin Pediatr Surg* 2005; 14:16-33.
5. Chen CC: Bronchogenic cyst in the interatrial septum with a single persistent left superior vena cava. *J Chin Med Assoc* 2006; 69:89-9.
6. Ibanez Aguirre J, Marti Cabane J, Bordas Rivas JM, Valenti Ponsa C, Erro Azcarate JM, De Simone P. A lump in the neck: cervical bronchogenic cyst mimicking a thyroid nodule. *Minerva Chir* 2006; 61:71-2.
7. Ustundag E, Iseri M, Keskin G, Yayla B, Muezzinoglu B. Cervical bronchogenic cysts in head and neck region: review of the literature. *J Laryngol Otol* 2005; 119(06): 419-23.
8. Ozel SK, Kazez A, Koseogullari AA, Akpolat N. Scapular bronchogenic cysts in children: case report and review of the literature. *Pediatr Surg Int* 2005; 21:843-45.
9. Reichelt O, Grieser T, Wunderlich H, Moller A, Schubert J. Brochogenic cyst: a rare differential diagnosis of retroperitoneal tumors. *Urol Int* 2000; 64: 216-19.
10. Zvulunov A, Amichai B, Grunwald MH, Avinoach I, Halevy S. Cutaneous bronchogenic cyst: delineation of a poorly recognized lesion. *Pediatr Dermatol* 1998; 15:277-81.
11. McAdams HP, Kirejczyk WM, Rosado-de-Christenson ML, Matsumoto S. Bronchogenic

- cyst: imaging features with clinical and histopathologic correlation. *Radiology* 2000; 217(2):441-6.
12. Mata JM, Caceres J, Lucaya J, Garcia-Conesa JA. CT of congenital malformations of the lung. *Radiographics*. 1990; 10(4): 651-74.
  13. Rappaport DC, Herman SJ, Weisbrod GL. Congenital bronchopulmonary diseases in adults: CT findings. *AJR Am J Roentgenol*. 1994; 162(6): 1295-9.
  14. Nakagawa M, Hara M, Oshima H, Shibamoto Y, Sato Y, Kondo S, et al. Pleural bronchogenic cysts: imaging findings. *J thorac Imaging* 2008; 23(4): 284-8.