

SPONTANEOUS HAEMOTHORAX A PRESENTATION OF ASYMPTOMATIC ESOPHAGEAL CARCINOMA

* Dr. S. Nazim Hussain Bokhari
MD (Chest), FCCP

SUMMARY

A large spontaneous haemothorax is rare but a life threatening situation. We wish to present a 69 years old smoker who had no preceeding symptoms of gastrointestinal system, yet presented with a massive spontaneous haemothorax as a presenting symptom of extensive infiltrative and nonresectable carcinoma of the esophagus.

CASE HISTORY

A 69 years old farmer from Gujranwala who was a chronic smoker presented at the A&E department of Shaikh Zayed Hospital Lahore with mild to moderate left sided chest pain and mild drowsiness of two days duration. Except for longstanding smoking he had no other current medical problem like diabetes or hypertension. Two years ago he was hospitalized for acute precordial pain with shortness of breath and was diagnosed to have acute inferior wall myocardial infarction. Subsequently he remained well except mild ischaemic episode 6 months ago. He continued to receive regular medication for cardiac problem and was able to carry on with his routine day to day activities,

About 4 days before his present admission, while walking in his farm he suddenly dropped down and had momentarily loss of consciousness. On regaining consciousness he appeared confused and had pain on left side of chest which increased on movement and deep breathing. He received primary symptomatic treatment from a local practitioner and presented at the hospital two days later. On systemic inquiry he had no remarkable complaints except mild difficulty with swallowing in solid food for the last one week.

There were no associated symptoms of cough fever, bowel disturbance or urinary complaint. His weight was steady and appetite normal.

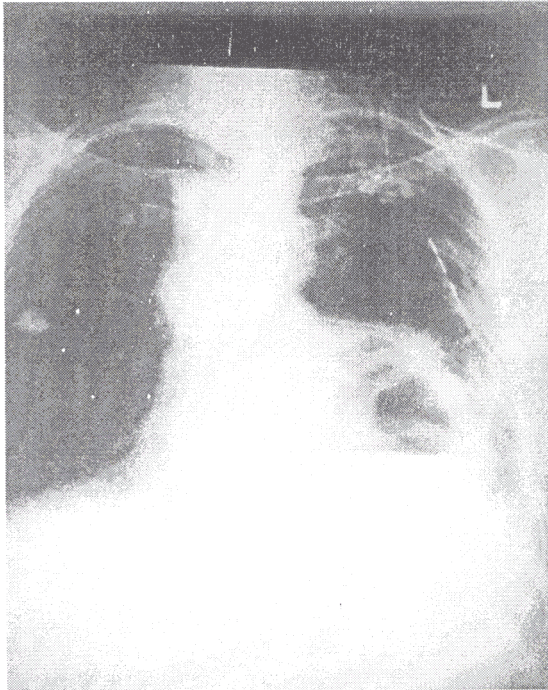
There was no remarkable past history except myocardial infarction 4 years ago for which he was on regular medication, which included B-blocker, Calcium antagonist and nitrates. Coronary Angiography had revealed two major vessel disease.

In the emergency department he appeared quiet comfortable and well oriented with normal vital functions including respiratory rate and no focal neurological signs. Examination of chest showed restricted movements on left side but no shift of mediastinum, percussion note was dull, breath sounds were diminished but no added sounds were audible. Rest of the systemic examination was unremarkable. A battery of tests were carried out which showed, Hb:10.1 Gm/dl, ESR: 60, TLC: 16x10⁹/L, complete urine examination: normal, ABGs showed; pH:7.36, PO₂:68.9 mmHg, PCO₂:41.7 mmHg, Liver function test including PT and APTT : normal, B.Sugar: 120 mg%, lipid profile and renal functions were also normal. Conventional chest radiograph showed opaque left

* Associate Professor Pulmonology,
Shaikh Zayed Hospital Lahore.

hemithorax due to large pleural effusion (Fig: 1).

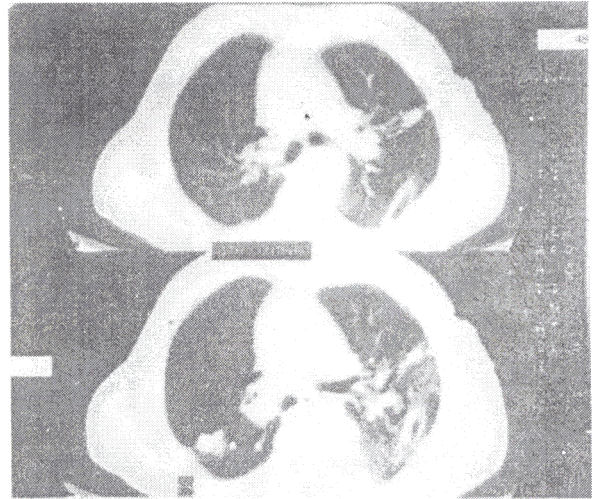
Fig: 2 Post intubation chest radiograph showing disappearance of fluid from costophrenic angle but a large thick wall cavity with air-fluid level is obvious.



While right lung showed multiple calcified spots. Ultrasound of the chest revealed large left sided effusion and a hypoechoic mass of 12x13 cm size with central necrosis was also observed along the posterior wall. Diagnostic thoracentesis under ultrasound guidance was performed which showed haemorrhagic effusion. Biochemical examination of the fluid showed Proteins: 6.7 Gm/dl, Sugar: 110 mg% (Blood Sugar : 120 mg%), LDH:328 iu/L, no acid fast bacilli on ZN staining and cytological examination showed no malignant cells.

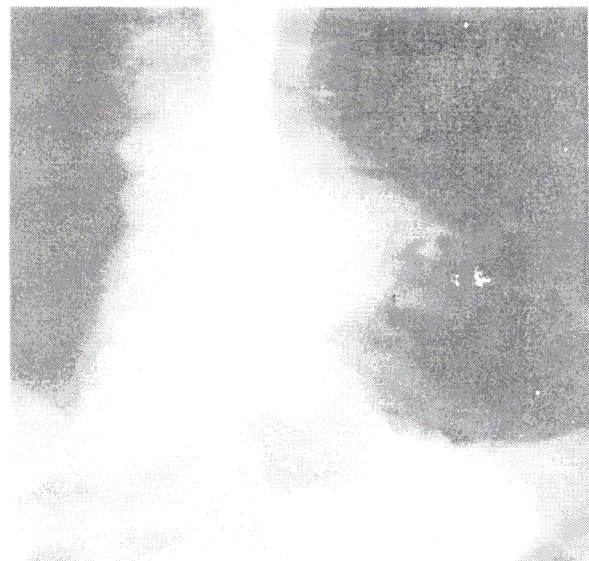Intercostal chest intubation was carried out which drained only about 200 ml of fluid which appeared almost like blood. Post intubation chest radiograph showed large air / fluid level still present inspite of disappearance of pleural fluid from costophrenic angle (Fig:2).

Fig: 2 CT Chest showing fluid collection along the posterior chest wall, but no mass lesion can be appreciated.



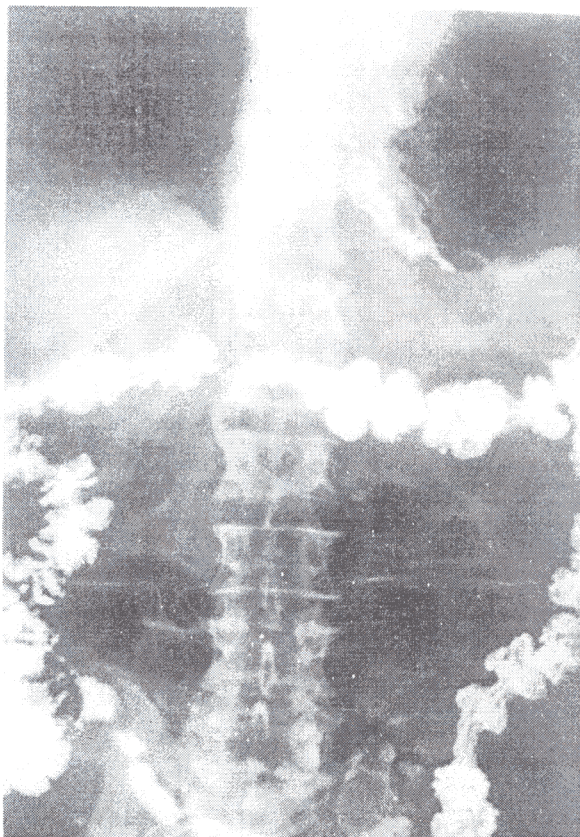
While lung was still not fully expanded. Computerized chest radiogram showed a large fluid collection in the lower and middle zones overlapping cardiac border. No mass was appreciable and no area of significant enhancement was noted (Fig:3).

Fig: 3 Gastrograffin swallow reveals indentation of lower esophagus and leakage of dye into the thick wall cavity.



However there were areas of pleural thickening, calcified foci and fibrocalcific changes in the lungs indicating old healed chronic inflammatory lesions. Repeat ultrasound of the chest was requested to review the early reporting of a mass lesion, which was noted again adjacent to apparently a loculated area of pleural effusion. About 200 ml of haemorrhagic fluid was aspirated using ultrasound guidance. Post aspiration x-ray of the chest showed clearing of chest but raised left dome of diaphragm and a big area with air / fluid levels within the chest appearing like gut loops. A barium meal and follow through was requested at this stage which revealed large filling defect at the lower end of esophagus, marked mucosal irregularity and leakage of barium into the cavity showing fluid level (Fig:4).

Fig: 4 Gastrograffin follow through shows large thick walled cavity communicating with esophagus and retaining dye



A thick walled cavitating mass in the paravertebral area was evident. The stomach and rest of gut showed normal transit of barium. Endoscopic oesophago-gastroscopy was performed which revealed an infiltrative growth at the lower end of esophagus. Histopathology of the biopsy specimen showed infiltrative undifferentiated carcinoma of the esophagus. For further management the patient was referred to the oncology department.

DISCUSSION

Only a few ml of blood when added to pleural effusion can render it haemorrhagic. Haemothorax is reserved for pleural effusions whose haematocrit level is at least 50% of the peripheral blood (1). Pleural fluid having Htc of as little as 5% of blood can appear just like blood. Causes of haemorrhagic effusion, besides trauma (2), include trauma, primary and metastatic neoplastic disease, bleeding or coagulation disorders, tuberculosis, rupture of an aneurysm (3), arteriovenous malformation (4), or a dilated blood vessel increased blood flow to lungs due to a shunt, bleeding from a sequestered lung segment (5), endometriosis or even ectopic pregnancy and rupture of mediastinal structures such as thymus, chickenpox pneumonia, long-term use of steroids (6) and in some remain undiagnosed inspite of exploratory thoracotomy.

Large haemothorax is generally rare and a life threatening situation. Patients generally present with symptoms of dyspnea and even shock which apparently look disproportionate to the amount of effusion on chest radiograph. General physical examination show signs of pleural effusion with possible shift of mediastinum to the opposite side. Diagnostic workup includes standard chest radiograph with both PA and lateral view, ultrasound examination of chest which is as sensitive as radiograph for early detection (7), and may be very valuable for more peripheral and solid lesions, in addition to quantification of the amount of fluid. In the presented case underlying mass lesion was missed on CT scanning but picked up by the ultrasound examination.

Diagnostic thoracentesis is mandatory to find out the blood contents, for cytochemistry and microbiological examination. Therapeutic aspiration through a wide bore needle is always needed (8) for better visualization of underlying structures, to avoid secondary infection, impairment of lung functions and development of subsequent pleural adhesions. Intrapleural fibrinolytic agents (Streptokinase and Urokinase) may help in dissolving clotted blood (9), computerized tomography or even angiography is highly valuable for three dimensional assessment of the normal and pathological structures.

Bronchoscopy or Thoracoscopy may be required when etiology remains obscured. Video-assisted Thoracoscopy may also assist in evacuation of blood from pleural cavity when chest tube drainage is inadequate (10,11). Further investigations may depend on the area of underlying pathology, as cardiovascular assessment may be required when leakage from a vascular channel has occurred, or abdominal endoscopy or laparoscopy may help when abdominal sub-diaphragmatic pathology is likely.

In case of large bleed, with daily tube aspirate of >100 ml; emergency surgery may be required. Overall about 20% of the haemothoraces require thoracotomy. Large spontaneous bleeds are generally due to a malignant underlying process and may require aggressive therapeutic and diagnostic approach.

REFERENCES

1. Light RW
Chylothorax, Haemothorax and Fibrothorax; in :J.F.Murray, J.A.Nidel, Eds.
Textbook of Respiratory Diseases.
Philadelphia, W.B.Saunders, 1994, p:2017-18
2. Yeam I, Sason C.
Haemothorax and Chylothorax; Curr. Opin. Pulm.Med. 1997,3(4):310-14
3. Cohen JD, Sahar G, Singer p, et al.
Massive spontaneous haemothorax as a presenting sign of aneurysmal rupture of the internal thoracic artery: A case report; J. Cardiovasc.Surg.Torin. 1998;39(3):383-85
4. Adegboyeg PA, Youh G, Adesokan A.
Recurrent massive haemothorax in Rendu Osler Weber Syndrome; SouthMed.J.1996,89(12):1193-6
5. Ilias L, Palfy G, Szonyi P, Taller A.
Massive haemothorax caused by intralobar pulmonary sequestration; Orv.Hetil, 1996;137(23):1263-5 (Hungarian).
6. Bauriedel G, Scheaiblmair M, Nabarex M, et al.
Spontaneous haemothorax in dermatomyositis and long-term corticosteroids Treatment; Dtsch.Med.Wochenschr. 1995,120(7):209-13 (German).
7. Ma OJ, Mateei JR
Traumatic ultrasound examination versus chest radiography in the detection of hemothorax; Ann. Emerg.Med; 1997,29(3):312-15.
8. Ali AT, Qi W.
Effectiveness of chest tube clamping in massive hemothorax; J. Trauma, 1995,38(1):59-62
9. Inci I, Ozceeli K, Ulku R, Tuna A, Eren N.
Intrapleural fibrinolytic treatment of traumatic clotted hemothorax; Chest, 1998;114(1):160-65
10. Lendreneau RJ, Keenan RJ, Hazelrigg SR, Mack MJ.
Thoracoscopy for empyema and hemothorax; Chest 1996,109(1):18-24
11. Mayer DM, Tissen ME, Wait MA, Estrera AS.
Early evacuation of traumatic retained hemothorax using Toracoscopy; a prospective randomized trial; Ann.Thor.Surg. 1997;64(5):1396-400